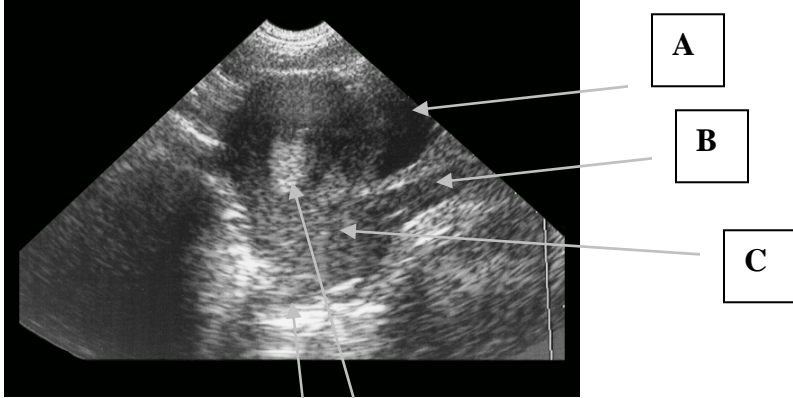

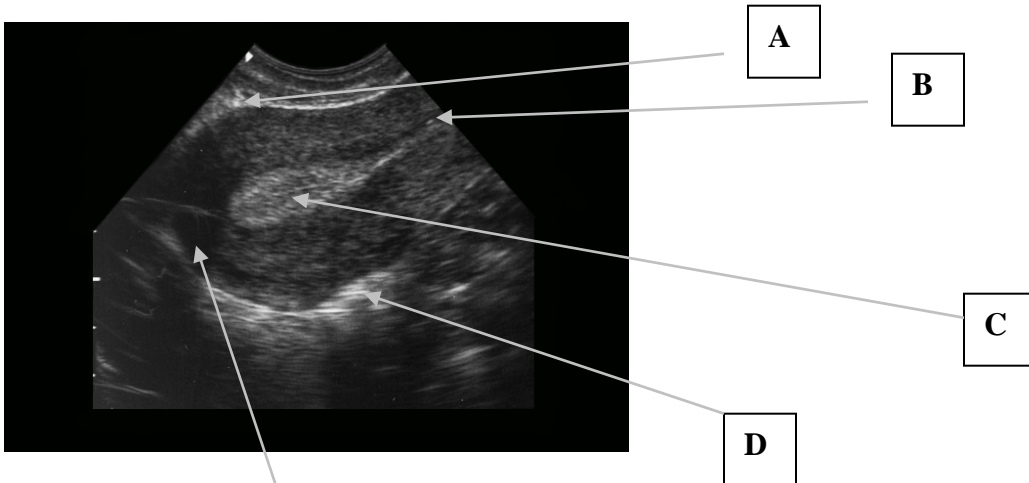
SLRHC Credentialing Examination
Pelvic



Identify:

- A. _____
- B. _____
- C. _____
- D. _____
- E. _____

F. This is a TRANSABDOMINAL/TRANSVAGINAL image.



Identify:

- A. _____
- B. _____
- C. _____
- D. _____
- E. _____

F. This is a TRANSABDOMINAL/TRANSVAGINAL image.

Please circle the single best answer:

- 1) The main indication for emergency sonography in 1st trimester pregnancy is to confirm:
 - A) Intrauterine pregnancy
 - B) Ovarian torsion
 - C) Fluid in the cul de sac
 - D) Ectopic pregnancy
 - E) Corpus lustrum cyst

- 2) A patient presents with a positive urine pregnancy test and vaginal bleeding in the 1st trimester. She is hemodynamically stable and a bedside emergency pelvic ultrasound is indeterminate. The next best step is:
 - A) Repeat bedside ultrasound in 30 min
 - B) Obtain a formal ultrasound and OB/Gyn consultation
 - C) Wait the results of the serum HCG to determine the next step
 - D) Discharge the patient home with instructions
 - E) Culdocentesis

- 3) The most common site for pooling of pelvic free fluid is:
 - A) Ano-rectal recess
 - B) Splenorenal recess
 - C) Hepatorenal recess
 - D) Anterior cul de sac
 - E) Posterior cul de sac

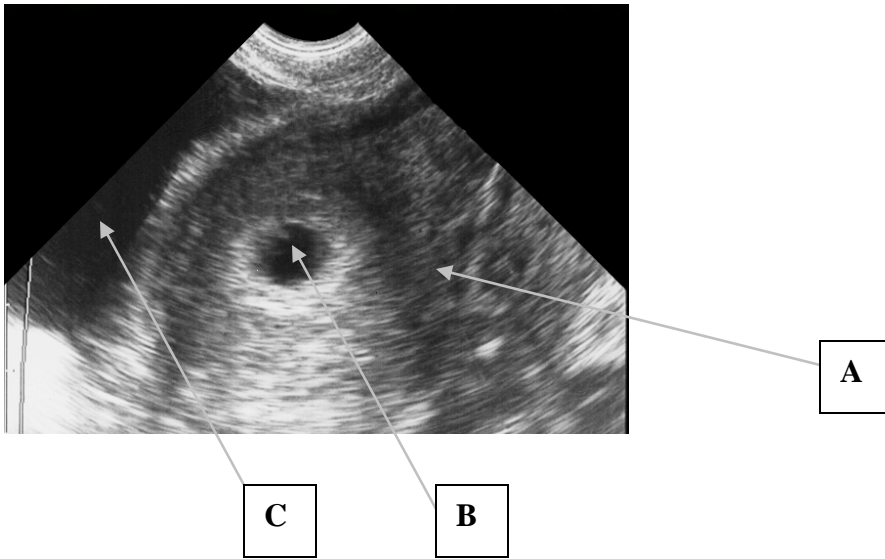
- 4) Transabdominal sonography of the uterus is best accomplished by a HIGH/LOW frequency probe.

- 5) Transvaginal sonography of the uterus is best accomplished by a HIGH/LOW frequency probe.

- 6) For optimal transabdominal pelvic ultrasound imaging, the bladder should be FULL/EMPTY.

- 7) For optimal transvaginal pelvic ultrasound imaging, the bladder should FULL/EMPTY.

- 8) Which agent is best for lubricating the outside sheath of a probe for vaginal sonography?
 - A) Conducting gel
 - B) Water-based lubricant
 - C) Bacitracin ointment
 - D) Sterile H₂O
 - E) None



Identify:

A. _____

B. _____

C. _____

D. This is a TRANSVAGINAL/TRANSABDOMINAL image. (Circle)

9) In relation to the iliac vessels, the ovary is anatomically located:

- A) Medial and posterior
- B) Medial and anterior
- C) Lateral and posterior
- D) Lateral and anterior
- E) No relationship

10) Which is the correct progression of pregnancy as visualized by pelvic sonography?

- A) Intradecidual sign, yolk sac, gestational sac, embryo with cardiac activity
- B) Intradecidual sign, gestational sac, yolk sac, embryo with cardiac activity
- C) Gestational sac, embryo with cardiac activity, yolk sac, intradecidual sign
- D) Gestational sac, intradecidual sign, embryo with cardiac activity, yolk sac
- E) Yolk sac, embryo with cardiac activity, gestational sac, intradecidual sign

11) True/False An empty uterus with an HCG < 1000 mIU/mL has low suspicion for ectopic pregnancy.

12) True/False According to SLR credentialing criteria, a clear double decidual sign is the first reliable evidence of an IUP.

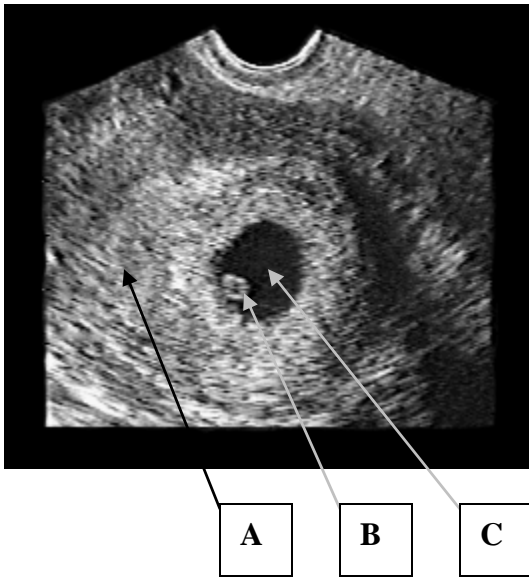
13) True/False According to SLR credentialing criteria, cardiac activity in the uterus in the embryo is the best evidence of an IUP.

14) True/False Patients on fertility medication have increased risk of a heterotopic with an IUP.

15) True/False Patients should be informed that emergency bedside ultrasound is a screening tool only and is not designed to detect most embryonic abnormalities.

16) A pregnancy implanted on the margin of the uterine wall and not in the cavity is:

- A) Corpus luteum cyst
- B) Hydatidiform mole
- C) Intrauterine pregnancy
- D) Interstitial ectopic pregnancy
- E) Blighted ovum



Identify:

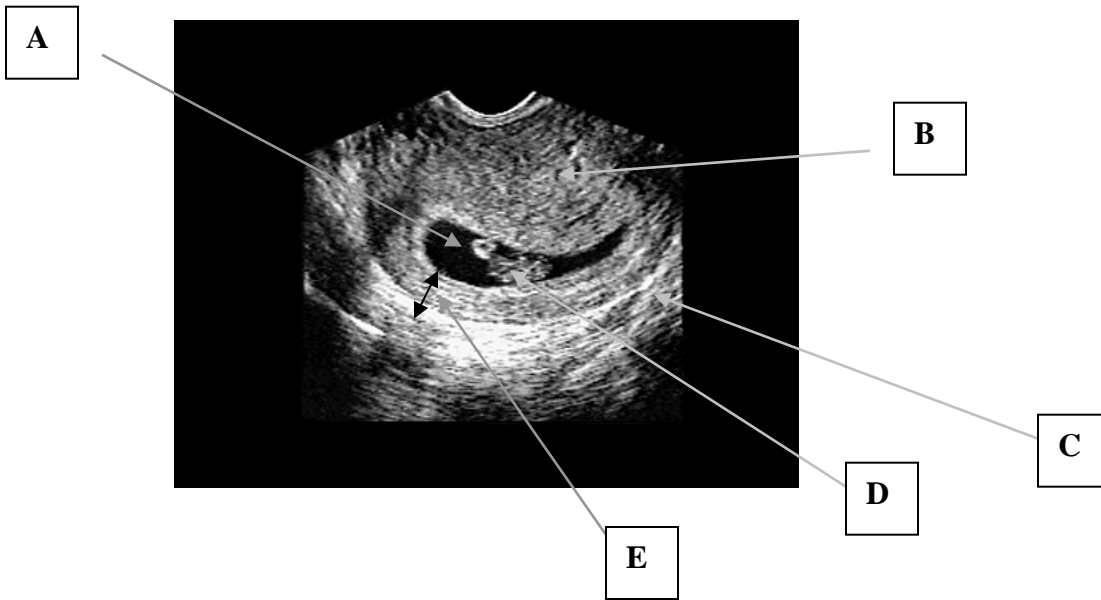
A) _____

B) _____

C) _____

D) This is a TRANSABDOMINAL/TRANSVAGINAL IMAGE

E) True/False This documents an early IUP.



Identify:

- A. _____
- B. _____
- C. _____
- D. _____
- E. _____

This is a TRANSABDOMINAL/TRANVAGINAL IMAGE
 True/False This documents an early IUP.

17) All of the following are risk factors for ectopic pregnancy except:

- A) IUD
- B) History of ectopic
- C) PID
- D) Early menarche
- E) Bilateral tubal ligation

18) The most common pelvic mass seen in early pregnancy is:

- A) Thecal lutein cyst
- B) Dermoid cyst
- C) Uterine leiomyoma
- D) Hydatiform mole
- E) Corpus luteum cyst

- 19) The typical probe frequency for transabdominal pelvic sonography:
- A) 1 -3 MHz
 - B) 3.5-5 MHz
 - C) 5-7.5 MHz
 - D) 9-11 MHz
 - E) 20 MHz
- 20) The typical probe frequency for transvaginal pelvic sonography:
- A) 1 -3 MHz
 - B) 3.5-5 MHz
 - C) 5-7.5 MHz
 - D) 9-11 MHz
 - E) 20 MHz
- 21) An empty gestational sac (no yolk sac or embryo) measuring 20mm or larger is commonly called:
- A) Corpus luteum cyst
 - B) Hydatiform mole
 - C) Dermoid cyst
 - D) Blighted ovum
 - E) Early IUP
- 22) A normal fetal heart rate for a 1st trimester pregnancy:
- A) 60
 - B) 110
 - C) 160
 - D) 240
 - E) 300
- 23) All of the following causes of pelvic pain should be considered in 1st trimester pregnancy once an intrauterine pregnancy is confirmed EXCEPT:
- A) Pericardial effusion
 - B) Ovarian torsion
 - C) Appendicitis
 - D) Renal calculus
 - E) Ligamentous strain