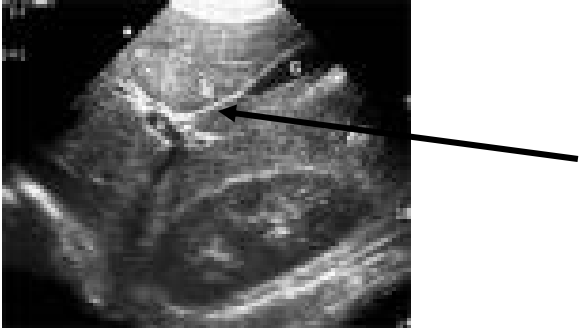


SLRHC Credentialing Examination
Biliary



1. Identify Pointed Arrow

2. List 4 elements of sonographic acute cholecystitis (include measurement parameters):

- A. _____
- B. _____
- C. _____
- D. _____

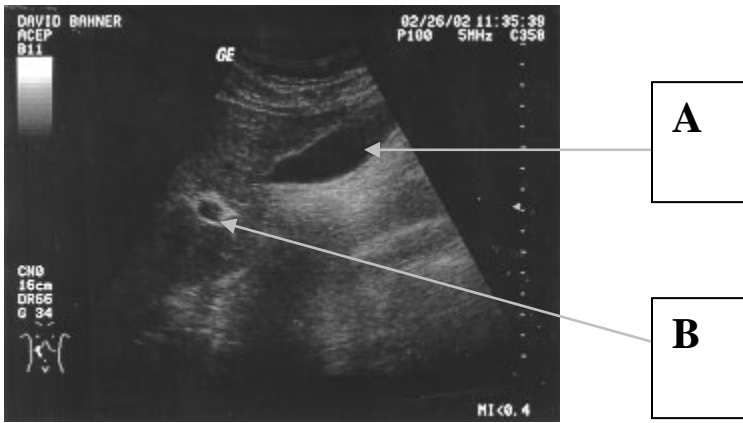
3. Which of the following is (are) causes of gallbladder wall thickening?

- A. Post prandial
- B. AIDS
- C. CHF
- D. Liver disease
- E. All of the above

4. T / F The common bile duct dilates with age.

5. The most sensitive sonographic finding for acute cholecystitis is:

- A. Gallbladder wall thickening
- B. Pericholecystic fluid
- C. Sonographic Murphy's sign
- D. Common bile duct dilation
- E. Sludge in the gallbladder



6. Identify structures

- A. _____
B. _____

7. T / F Patient positioning is essential for gallbladder imaging